



Protocol for the Examination of Cystectomy Specimens From Patients With Carcinoma of the Urinary Bladder

Version: 4.1.0.0

Protocol Posting Date: June 2021

CAP Laboratory Accreditation Program Protocol Required Use Date: March 2022

The changes included in this current protocol version affect accreditation requirements. The new deadline for implementing this protocol version is reflected in the above accreditation date.

For accreditation purposes, this protocol should be used for the following procedures AND tumor types:

Procedure	Description
Cystectomy	Includes specimens designated partial, total or radical cystectomy, radical cystoprostatectomy (for bladder cancer), and anterior exenterations
Tumor Type	Description
Carcinomas	Includes invasive carcinomas of the urinary tract, including urothelial carcinoma, its morphological variants, and other carcinoma (squamous cell carcinoma, adenocarcinoma, Müllerian carcinoma, neuroendocrine carcinoma, and sarcomatoid carcinoma) [#]

[#] *This protocol is recommended for reporting noninvasive urothelial tumors (papillary and flat), but it is not required for accreditation purposes.*

This protocol is NOT required for accreditation purposes for the following:

Procedure
Biopsy, transurethral resection of the bladder tumor [#] (TURBT), or enucleations (consider Urinary Bladder Biopsy protocol)
Primary resection specimen with no residual cancer (eg, following neoadjuvant therapy)
Cytologic specimens

[#] *Transurethral resection of a bladder tumor is NOT considered to be the definitive resection specimen, even though the entire cancer may be removed.*

The following tumor types should NOT be reported using this protocol:

Tumor Type
Urachal Carcinoma
Lymphoma (consider the Hodgkin or non-Hodgkin Lymphoma protocols)
Sarcoma (consider the Soft Tissue protocol)

Authors

Gladell P. Paner, MD*; Ming Zhou, MD, PhD*; John R. Srigley, MD*; Lara R. Harik, MD; Mahul B. Amin, MD; Robert Allan, MD; Brett Delahunt, MD; Bernard H. Bochner, MD; Jonathan I. Epstein, MD; David J. Grignon, MD; Peter A. Humphrey, MD, PhD; Rodolfo Montironi, MD; Jason Pettus, MD; Victor E. Reuter, MD.

With guidance from the CAP Cancer and CAP Pathology Electronic Reporting Committees.

* Denotes primary author.

Accreditation Requirements

This protocol can be utilized for a variety of procedures and tumor types for clinical care purposes. For accreditation purposes, only the definitive primary cancer resection specimen is required to have the core and conditional data elements reported in a synoptic format.

- Core data elements are required in reports to adequately describe appropriate malignancies. For accreditation purposes, essential data elements must be reported in all instances, even if the response is “not applicable” or “cannot be determined.”
- Conditional data elements are only required to be reported if applicable as delineated in the protocol. For instance, the total number of lymph nodes examined must be reported, but only if nodes are present in the specimen.
- Optional data elements are identified with “+” and although not required for CAP accreditation purposes, may be considered for reporting as determined by local practice standards.

The use of this protocol is not required for recurrent tumors or for metastatic tumors that are resected at a different time than the primary tumor. Use of this protocol is also not required for pathology reviews performed at a second institution (ie, secondary consultation, second opinion, or review of outside case at second institution).

Synoptic Reporting

All core and conditionally required data elements outlined on the surgical case summary from this cancer protocol must be displayed in synoptic report format. Synoptic format is defined as:

- Data element: followed by its answer (response), outline format without the paired Data element: Response format is NOT considered synoptic.
- The data element should be represented in the report as it is listed in the case summary. The response for any data element may be modified from those listed in the case summary, including “Cannot be determined” if appropriate.
- Each diagnostic parameter pair (Data element: Response) is listed on a separate line or in a tabular format to achieve visual separation. The following exceptions are allowed to be listed on one line:
 - Anatomic site or specimen, laterality, and procedure
 - Pathologic Stage Classification (pTNM) elements
 - Negative margins, as long as all negative margins are specifically enumerated where applicable
- The synoptic portion of the report can appear in the diagnosis section of the pathology report, at the end of the report or in a separate section, but all Data element: Responses must be listed together in one location

Organizations and pathologists may choose to list the required elements in any order, use additional methods in order to enhance or achieve visual separation, or add optional items within the synoptic report. The report may have required elements in a summary format elsewhere in the report IN ADDITION TO but not as replacement for the synoptic report ie, all required elements must be in the synoptic portion of the report in the format defined above.

Summary of Changes

v 4.1.0.0

- General Reformatting
- Revised Margins Section
- Revised Lymph Nodes Section
- Added Distant Metastasis Section
- Removed pTX and pNX Staging Classification
- Reformat Tumor Extent Section

Reporting Template

Protocol Posting Date: June 2021

Select a single response unless otherwise indicated.

CASE SUMMARY: (URINARY BLADDER: Cystectomy, Anterior Exenteration)

Standard(s): AJCC-UICC 8

This protocol is recommended for reporting noninvasive urothelial tumors (papillary and flat), but it is not required for accreditation purposes.

SPECIMEN (Note [A](#))

Procedure

- Partial cystectomy
- Radical cystectomy (total cystectomy)
- Radical cystoprostatectomy
- Anterior exenteration
- Other (specify): _____
- Not specified

TUMOR

Tumor Site (select all that apply)

- Trigone
- Right lateral wall
- Left lateral wall
- Anterior wall
- Posterior wall
- Dome
- Other (specify): _____
- Cannot be determined: _____

Histologic Type (Note [B](#)) (select all that apply)

Urothelial

- Papillary urothelial carcinoma, noninvasive
- Papillary urothelial carcinoma, invasive
- Urothelial carcinoma in situ
- Urothelial carcinoma, invasive
- Urothelial carcinoma, nested (including large nested) variant
- Urothelial carcinoma, microcystic variant
- Urothelial carcinoma, micropapillary variant
- Urothelial carcinoma, lymphoepithelioma-like variant
- Urothelial carcinoma, plasmacytoid / signet ring cell / diffuse
- Urothelial carcinoma, sarcomatoid variant
- Urothelial carcinoma, giant cell variant
- Urothelial carcinoma, poorly differentiated variant
- Urothelial carcinoma, lipid-rich variant
- Urothelial carcinoma, clear cell variant

___ Urothelial carcinoma with squamous differentiation

+Percentage of Squamous Differentiation

___ Specify percentage: _____ %

___ Other (specify): _____

___ Cannot be determined

___ Urothelial carcinoma with glandular differentiation

+Percentage of Glandular Differentiation

___ Specify percentage: _____ %

___ Other (specify): _____

___ Cannot be determined

___ Urothelial carcinoma with trophoblastic differentiation

+Percentage of Trophoblastic Differentiation

___ Specify percentage: _____ %

___ Other (specify): _____

___ Cannot be determined

___ Urothelial carcinoma with Müllerian differentiation

+Percentage of Müllerian Differentiation

___ Specify percentage: _____ %

___ Other (specify): _____

___ Cannot be determined

Squamous

___ Squamous cell carcinoma

___ Verrucous carcinoma

___ Squamous cell carcinoma in situ (no invasive carcinoma identified)

Glandular

___ Adenocarcinoma

___ Adenocarcinoma, enteric

___ Adenocarcinoma, mucinous

___ Adenocarcinoma, mixed

___ Adenocarcinoma in situ (no invasive carcinoma identified)

Tumors of Müllerian type

___ Clear cell carcinoma

___ Endometrioid carcinoma

Neuroendocrine Tumors

___ Small cell neuroendocrine carcinoma

+Percentage of Small Cell Neuroendocrine Component

___ Specify percentage: _____ %

___ Other (specify): _____

___ Cannot be determined

___ Large cell neuroendocrine carcinoma

+Percentage of Large Cell Neuroendocrine Component

___ Specify percentage: _____ %

___ Other (specify): _____

___ Cannot be determined

___ Well-differentiated neuroendocrine tumor

+Percentage of Well-differentiated Neuroendocrine Component

___ Specify percentage: _____ %

___ (Other specify): _____

___ Cannot be determined

___ Other histologic type not listed (specify): _____

+Histologic Type Comment: _____

Histologic Grade (Note C)

For urothelial carcinoma, other variants, or divergent differentiation

___ Low-grade

___ High-grade

For squamous cell carcinoma or adenocarcinoma

___ G1, well-differentiated

___ G2, moderately differentiated

___ G3, poorly differentiated

___ GX, cannot be assessed: _____

Other

___ Other (specify): _____

___ Cannot be assessed: _____

___ Not applicable

Tumor Size

___ Greatest dimension in Centimeters (cm): _____ cm

+Additional Dimension in Centimeters (cm): ___ x ___ cm

___ Cannot be determined (explain): _____

Tumor Extent (Note D) (select all that apply)

___ Noninvasive papillary carcinoma

___ Urothelial carcinoma in situ

___ Invades lamina propria (subepithelial connective tissue)

___ Invades superficial muscularis propria (inner half)

___ Invades deep muscularis propria (outer half)

___ Invades perivesical soft tissue microscopically

___ Invades perivesical soft tissue macroscopically (extravesical mass)

___ Invades adjacent structure(s)#

___ Prostate (transmural invasion from the bladder tumor) (Note D, Fig. 1)(Note D)

___ Seminal vesicles

___ Uterus

___ Vagina

___ Adnexa

___ Pelvis wall

___ Abdominal wall

___ Rectum

___ Other (specify): _____

___ Cannot be determined: _____

___ No evidence of primary tumor

Use the Urethral checklist for tumors that involve the urethral mucosa without invasion, tumors that involve the urethral mucosa with invasion of subepithelial connective tissue / prostate stroma, or tumors that involve prostatic ducts and acini with or without stromal invasion.

Lymphovascular Invasion (Note E)

___ Not identified

___ Present

___ Cannot be determined: _____

+Tumor Configuration (select all that apply)

- Papillary
- Solid / nodule
- Flat
- Ulcerated
- Other (specify): _____
- Cannot be determined: _____

+Tumor Comment: _____

MARGINS (Note F)

For partial cystectomies, if the specimen is received unoriented precluding identification of specific margins, it should be denoted here.

Margin Status for Invasive Tumor

All margins negative for invasive tumor

+Closest Margin(s) to Invasive tumor (select all that apply)

- Right ureteral: _____
- Left ureteral: _____
- Urethral: _____
- Soft tissue: _____
- Other margin(s) (specify)#: _____

+Distance from Invasive Tumor to Closest Margin

Specify in Millimeters (mm)

- Exact distance: _____ mm
- Other (specify): _____
- Cannot be determined: _____

Invasive tumor present at margin

+Margin(s) Involved by Invasive Tumor (select all that apply)

- Right ureteral: _____
- Left ureteral: _____
- Urethral: _____
- Soft tissue: _____
- Other margin(s) (specify)#: _____
- Other (specify): _____
- Cannot be determined (explain): _____
- Not applicable

Margin Status for Carcinoma in situ / Noninvasive Papillary Urothelial Carcinoma

Non-invasive tumors include flat urothelial carcinoma in situ and non-invasive papillary urothelial carcinoma

All margins negative for carcinoma in situ / noninvasive papillary urothelial carcinoma

+Closest Margin(s) to Carcinoma in situ / Noninvasive Papillary Urothelial Carcinoma (select all that apply)

- Right ureteral: _____
- Left ureteral: _____
- Urethral: _____
- Other (specify): _____
- Cannot be determined (explain): _____

___ Carcinoma in situ / noninvasive papillary urothelial carcinoma present at margin
+Margin(s) Involved by Carcinoma in situ / Noninvasive Papillary Urothelial Carcinoma (select all that apply)

- ___ Right ureteral: _____
- ___ Left ureteral: _____
- ___ Urethral: _____
- ___ Other (specify): _____
- ___ Cannot be determined (explain): _____
- ___ Other (specify): _____
- ___ Cannot be determined (explain): _____
- ___ Not applicable

+Margin Comment: _____

REGIONAL LYMPH NODES

Regional Lymph Node Status

- ___ Not applicable (no regional lymph nodes submitted or found)
- ___ Regional lymph nodes present
 - ___ All regional lymph nodes negative for tumor
 - ___ Tumor present in regional lymph node(s)

Number of Lymph Nodes with Tumor

- ___ Exact number (specify): _____
- ___ At least (specify): _____
- ___ Other (specify): _____
- ___ Cannot be determined (explain): _____

+Size of Largest Nodal Metastatic Deposit

Specify in Centimeters (cm)

- ___ Exact size: _____ cm
- ___ At least: _____ cm
- ___ Greater than: _____ cm
- ___ Less than: _____ cm
- ___ Other (specify): _____
- ___ Cannot be determined (explain): _____

+Nodal Site with Largest Metastatic Deposit (specify site): _____

+Size of Largest Lymph Node with Tumor

Specify in Centimeters (cm)

- ___ Exact size: _____ cm
- ___ At least: _____ cm
- ___ Greater than: _____ cm
- ___ Less than: _____ cm
- ___ Other (specify): _____
- ___ Cannot be determined (explain): _____

+Largest Lymph Node with Tumor (specify site): _____

+Extranodal Extension (ENE)

- Not identified
- Present
- Cannot be determined: _____
- Other (specify): _____
- Cannot be determined (explain): _____

Number of Lymph Nodes Examined

- Exact number (specify): _____
- At least (specify): _____
- Other (specify): _____
- Cannot be determined (explain): _____

+Regional Lymph Node Comment: _____

DISTANT METASTASIS

Distant Site(s) Involved, if applicable# (select all that apply)

- Not applicable
- Non-regional lymph node(s): _____
- Other site(s), excluding non-regional lymph nodes (specify): _____
- Cannot be determined: _____

PATHOLOGIC STAGE CLASSIFICATION (pTNM, AJCC 8th Edition) (Note [G](#))

Reporting of pT, pN, and (when applicable) pM categories is based on information available to the pathologist at the time the report is issued. As per the AJCC (Chapter 1, 8th Ed.) it is the managing physician's responsibility to establish the final pathologic stage based upon all pertinent information, including but potentially not limited to this pathology report.

TNM Descriptors (select all that apply)

- Not applicable: _____
- m (multiple primary tumors)
- r (recurrent)
- y (post-treatment)

pT Category

- pT not assigned (cannot be determined based on available pathological information)
- pT0: No evidence of primary tumor
- pTa: Non-invasive papillary carcinoma
- pTis: Urothelial carcinoma *in situ*: "flat tumor"
- pT1: Tumor invades lamina propria (subepithelial connective tissue)
- pT2: Tumor invades muscularis propria*
- pT2a: Tumor invades superficial muscularis propria (inner half)
- pT2b: Tumor invades deep muscularis propria (outer half)
- pT2 (subcategory cannot be determined)
- pT3: Tumor invades perivesical soft tissue*
- pT3a: Tumor invades perivesical soft tissue microscopically
- pT3b: Tumor invades perivesical soft tissue macroscopically (extravesicular mass)
- pT3 (subcategory cannot be determined)

pT4: Extravesical tumor directly invades any of the following: prostatic stroma, seminal vesicles, uterus, vagina, pelvic wall, abdominal wall

Approved

- pT4a: Extravesical tumor invades directly into prostatic stroma, uterus, or vagina
 pT4b: Extravesical tumor invades pelvic wall, abdominal wall
 pT4 (subcategory cannot be determined)

pN Category

- pN not assigned (no nodes submitted or found)
 pN not assigned (cannot be determined based on available pathological information)
 pN0: No lymph node metastasis
 pN1: Single regional lymph node metastasis in the true pelvis (perivesical, obturator, internal and external iliac, or sacral lymph node)
 pN2: Multiple regional lymph node metastasis in the true pelvis (perivesical, obturator, internal and external iliac, or sacral lymph node)
 pN3: Lymph node metastasis to the common iliac lymph nodes

pM Category (required only if confirmed pathologically)

- Not applicable - pM cannot be determined from the submitted specimen(s)
pM1: Distant metastasis
 pM1a: Distant metastasis limited to lymph nodes beyond the common iliacs
 pM1b: Non-lymph-node distant metastases
 pM1 (subcategory cannot be determined)

ADDITIONAL FINDINGS (Note [C](#))**+Associated Epithelial Lesions (select all that apply)**

- None identified
 Urothelial papilloma
 Urothelial papilloma, inverted type
 Papillary urothelial neoplasm, low malignant potential (PUNLMP)
 Urothelial proliferation of uncertain malignant potential
 Urothelial dysplasia
 Other (specify): _____
 Cannot be determined: _____

+Additional Findings (select all that apply)

- Urothelial dysplasia
 Adenocarcinoma of prostate (use checklist for carcinoma of prostate)
 Inflammation / regenerative changes
 Therapy-related changes (specify): _____
 Cystitis cystica et glandularis
 Keratinizing squamous metaplasia
 Intestinal metaplasia
 Other (specify): _____

COMMENTS

Comment(s): _____

Explanatory Notes

A. Sections for Microscopic Evaluation

Bladder

Sections of bladder for microscopic evaluation for cystectomy specimens, several representative sections of the tumor, including the macroscopically deepest penetration, should be sampled. Submit several sections of the mucosa remote from the carcinoma, especially if abnormal, including the lateral wall(s), dome, and trigone. Submit one section of ureteral margin, unless submitted separately as frozen section specimens, and 1 section of urethral margin. If a long segment of the ureter(s) is present, then additional sections from the mid-portion may be necessary, as urothelial cancer often is multifocal.

Prostate and Prostatic Urethra

Prostatic urethral involvement should be carefully investigated in cystectomy specimens. Sections should include the prostatic urethra, including at the margin and with the surrounding prostatic parenchyma. Representative sections of the peripheral zone, central zone, and seminal vesicles should be included. Close gross examination may help target sampling of selective abnormal-appearing areas.

Lymph Nodes

Submit one section from each grossly positive lymph node. All other lymph nodes should be entirely submitted, as presence of nodal disease may be used as an indication for adjuvant therapy. Lymph nodes may be grossly or microscopically detected in the perivesical fat.

Other Tissues

Submit one or more sections of uterus (as indicated) and one or more sections of vagina, seminal vesicles, and other organs (as indicated). If the tumor grossly appears to invade the prostate, uterus, or vagina, sections should be targeted, such that the relationship of the infiltrating tumor in the bladder wall and the adjacent viscus is clearly demonstrable.

B. Histologic Type

The vast majority (more than 95%) of carcinomas of the urinary bladder, renal pelvis, and ureter are urothelial cell in origin. The most recent 2016 World Health Organization (WHO) classification of tumors of the urothelial tract, including urethra, urinary bladder, ureter, and renal pelvis, is provided in this note. Benign tumors are included in this classification because, within the same patient, a spectrum of differentiation from benign to malignant tumors may be seen in the bladder, either at the same time or over the clinical course of the disease. Also, clinicians stage most tumors irrespective of histologic grade.^{[1](#)[2](#)[3](#)[4](#)[5](#)[6](#)[7](#)[8](#)[9](#)} The distinction between a urothelial carcinoma with divergent squamous, glandular, or Müllerian differentiation and a pure squamous cell carcinoma, adenocarcinoma or Müllerian is rather arbitrary. Most authorities, including the 2016 WHO classification, require a pure histology of squamous cell carcinoma, adenocarcinoma or Müllerian to designate a tumor as such, all others with recognizable papillary, invasive, or flat carcinoma in situ (CIS) urothelial component being considered as urothelial carcinoma with divergent differentiation. A malignant neoplasm with small cell neuroendocrine carcinoma component arising in the urinary tract is designated as small cell carcinoma.

2016 WHO Classification of Tumors of the Urothelial Tract

Urothelial tumors

Infiltrating urothelial carcinoma

- Nested, including large nested
- Microcystic
- Micropapillary
- Lymphoepithelioma-like
- Plasmacytoid/signet ring cell/diffuse
- Sarcomatoid
- Giant cell
- Poorly differentiated

Noninvasive urothelial lesions

- Urothelial carcinoma in situ
- Noninvasive papillary urothelial carcinoma, low grade
- Noninvasive papillary urothelial carcinoma, high grade
- Papillary urothelial neoplasm of low malignant potential
- Urothelial papilloma
- Inverted urothelial papilloma
- Urothelial proliferation of uncertain malignant potential
- Urothelial dysplasia

Squamous cell neoplasms

- Squamous cell carcinoma
- Verrucous carcinoma
- Squamous cell papilloma

Glandular neoplasms

- Adenocarcinoma, NOS
 - Enteric

Mucinous

Mixed

Villous adenoma

Urachal carcinoma

Tumors of Mullerian type

Clear cell carcinoma

Endometrioid carcinoma

Neuroendocrine tumors

Small cell neuroendocrine carcinoma

Large cell neuroendocrine carcinoma

Well-differentiated neuroendocrine tumor

Paraganglioma

References

1. Amin MB, Murphy WM, Reuter VE, et al. Controversies in the pathology of transitional cell carcinoma of the urinary bladder. In: Rosen PP, Fechner RE, eds. *Reviews of Pathology*. Vol. 1. Chicago, IL: ASCP Press; 1996.
2. Reuter VE. The urothelial tract: renal pelvis, ureter, urinary bladder, and urethra. In: Mills Se, Carter D, Greenson JK, Oberman HA, Reuter V, Stoler MH, eds. *Sternberg's Diagnostic Surgical Pathology*. 4th ed. Philadelphia, PA: Lippincott Williams and Wilkins; 2004.
3. Amin MB, Young RH. Intraepithelial lesions of the urinary bladder with a discussion of the histogenesis of urothelial neoplasia. *Semin Diagn Pathol*. 1997;14(2):84-97.
4. Eble JN, Young RH. Carcinoma of the urinary bladder: a review of its diverse morphology. *Semin Diagn Pathol*. 1997;14(2):98-108.
5. Mostofi FK, Davis CJ, Sesterhenn IA. Histologic typing of urinary bladder tumors. In: *World Health Organization International Histologic Classification of Tumours*. 2nd ed. Heidelberg, Germany: Springer-Verlag, Berlin; 1999.
6. Eble JN, Sauter G, Epstein JI, Sesterhenn IA. Tumors of the urinary system. In: *World Health Organization Classification of Tumours: Pathology and Genetics of Tumours of the Urinary System and Male Genital Organs*. Lyon, France: IARC Press; 2004.
7. Moch H, Humphrey PA, Ulbright TM, Reuter VE. *WHO Classification of Tumours of the Urinary System and Male Genital Organs*. Geneva, Switzerland: WHO Press; 2016.
8. Murphy WM, Grignon DJ, Perlman EJ. Tumors of the urinary bladder. In: *Tumors of the Kidney, Bladder, and Related Urinary Structures. AFIP Atlas of Tumor Pathology*. Series 4. Washington, DC: American Registry of Pathology; 2004.
9. Epstein JI, Amin MB, Reuter VR, Mostofi FK, the Bladder Consensus Conference Committee. The World Health Organization/International Society of Urological Pathology Consensus classification of urothelial (transitional cell) neoplasms of the urinary bladder. *Am J Surg Pathol*. 1998;22:1435-1448.

C. Histologic Grade

Flat intraepithelial lesions and papillary and invasive lesions are graded separately.^{1,2,3,4,5,6,7,8} There has been significant controversy in the classification of these lesions. Flat lesions were graded as mild, moderate, and severe dysplasia and carcinoma in situ; or atypical hyperplasia and carcinoma in situ; or dysplasia and carcinoma in situ.^{9,10} Papillary lesions were classified as papillomas (grade 0) and transitional cell carcinomas, grades I, II and III; or as papillomas, low-grade and high-grade transitional cell carcinomas.^{4,5,6} Due to variable classification systems and the need for a universally acceptable system, the World Health Organization/International Society of Urological Pathology (WHO/ISUP) consensus classification was proposed.⁴ This system is adopted in the WHO 2004 classification¹ and 2004 Armed Forces Institute of Pathology (AFIP) fascicle,³ and has been validated by many studies to be prognostically significant. The 2016 WHO system used essentially the same classification with minor modification.² Other systems (that were being used previously) may still be used according to institutional preference. Tumor grade according to both the WHO/ISUP (1998)⁴ / WHO (2004)¹ system and the older WHO (1973)⁶ system may be concurrently used.

2004 WHO / ISUP Consensus Classification for Urothelial Lesions

Normal

Normal[#]

Hyperplasia

Flat hyperplasia

Papillary hyperplasia

Flat Lesions with Atypia

Reactive (inflammatory) atypia

Atypia of unknown significance

Dysplasia (low-grade intraurothelial neoplasia)[#]

Carcinoma in situ (high-grade intraurothelial neoplasia)^{##}

Papillary Neoplasms

Papilloma

Inverted papilloma

Papillary neoplasm of low malignant potential

Papillary carcinoma, low-grade

Papillary carcinoma, high-grade^{###}

Invasive Neoplasms

Lamina propria invasion

Muscularis propria (detrusor muscle) invasion

[#] May include cases formerly diagnosed as "mild dysplasia."

Includes cases with "severe dysplasia."

Option exists to add comment as to the presence of marked anaplasia.

Flat and papillary urothelial hyperplasia has been renamed as "urothelial proliferation of uncertain malignant potential" in the 2016 WHO classification.

Squamous carcinomas and adenocarcinomas may be graded as well-differentiated, moderately differentiated, and poorly differentiated.

References

1. Eble JN, Sauter G, Epstein JI, Sesterhenn IA. Tumors of the urinary system. In: *World Health Organization Classification of Tumours: Pathology and Genetics of Tumours of the Urinary System and Male Genital Organs*. Lyon, France: IARC Press; 2004.
2. Moch H, Humphrey PA, Ulbright TM, Reuter VE. *WHO Classification of Tumours of the Urinary System and Male Genital Organs*. Geneva, Switzerland: WHO Press; 2016.
3. Murphy WM, Grignon DJ, Perlman EJ. Tumors of the urinary bladder. In: *Tumors of the Kidney, Bladder, and Related Urinary Structures. AFIP Atlas of Tumor Pathology. Series 4*. Washington, DC: American Registry of Pathology; 2004.
4. Epstein JI, Amin MB, Reuter VR, Mostofi FK, the Bladder Consensus Conference Committee. The World Health Organization/ International Society of Urological Pathology Consensus classification of urothelial (transitional cell) neoplasms of the urinary bladder. *Am J Surg Pathol*. 1998;22:1435-1448.
5. Murphy WM, Beckwith JB, Farrow GM. Tumors of the kidney, bladder, and related urinary structures. In: *Atlas of Tumor Pathology. 3rd series. Fascicle 11*. Washington, DC: Armed Forces Institute of Pathology; 1994.
6. Mostofi FK. Histological typing of urinary bladder tumours. In: *WHO Histological Classification of Tumours*. No. 10. Geneva, Switzerland: World Health Organization; 1973.
7. Bergkvist A, Ljungqvist A, Moberger G. Classification of bladder tumors based on the cellular pattern. *Acta Chir Scand*. 1965;130:371-378.
8. Friedell GH, Bell JR, Burney SW, Soto EA, Tiltman AJ. Histopathology and classification of urinary bladder carcinoma. *Urol Clin North Am*. 1976;3:265-227.
9. Amin MB, Murphy WM, Reuter VE, et al. Controversies in the pathology of transitional cell carcinoma of the urinary bladder. In: Rosen PP, Fechner RE, eds. *Reviews of Pathology*. Vol. 1. Chicago, IL: ASCP Press; 1996.
10. Amin MB, Young RH. Intraepithelial lesions of the urinary bladder with a discussion of the histogenesis of urothelial neoplasia. *Semin Diagn Pathol*. 1997;14(2):84-97.

D. Extent of Invasion

A critical role of the surgical pathologist is to diagnose the depth and extent of invasion into the subepithelial connective tissue/lamina propria/submucosa (pT1), muscularis propria (pT2), or beyond (pT3 or pT4).^{1,2,3} In papillary tumors, invasion occurs most often at the base of the tumor and very infrequently in the stalk. In the urinary bladder, a tumor infiltrating the lamina propria (pT1) is sometimes overdiagnosed as vascular invasion; hence, caution should be exercised when diagnosing this feature, which in some cases may be supported by performing immunohistochemical studies for endothelial markers.⁴

Involvement of the prostate gland may occur in several different patterns. Tumors (flat carcinoma in situ, papillary or invasive carcinoma) can first spread along the prostatic urethral mucosa and prostate glands and subsequently invade prostatic stroma (transurethral mucosal route) (Figure 1, B). Tumors may also invade through the bladder wall and the base of the prostate directly into the prostate gland (Figure 1, A, straight arrow).⁵ Tumors can also invade into extravesical fat and then extend back into the prostate gland

(Figure 1, B, curved arrow). The latter two routes are considered direct transmural invasion. The American Joint Committee on Cancer (AJCC) 8th edition staging manual defines direct extension of urinary bladder cancer into the prostate gland as T4 disease and excludes transurethral mucosal prostatic stroma invasion from the pT4a staging status. However, there is limited data on the best methodology to stage urothelial carcinoma that concurrently involves the urinary bladder and the prostatic urethra. In patients who have a large urinary bladder carcinoma that has invaded through the full thickness of the bladder wall and thereby secondarily involves the prostatic stroma, a T4 stage should be assigned per urinary bladder staging. In other circumstances in which involvement by urothelial carcinoma is seen in both sites, separate urinary bladder and prostatic urethral staging should be assigned. Transmucosal route into prostatic stroma from a bladder cancer without transmural prostatic stromal invasion is now categorized as pT2 per urethral cancer staging, and the concomitant bladder proper cancer is given a separate stage category according to the bladder cancer staging.

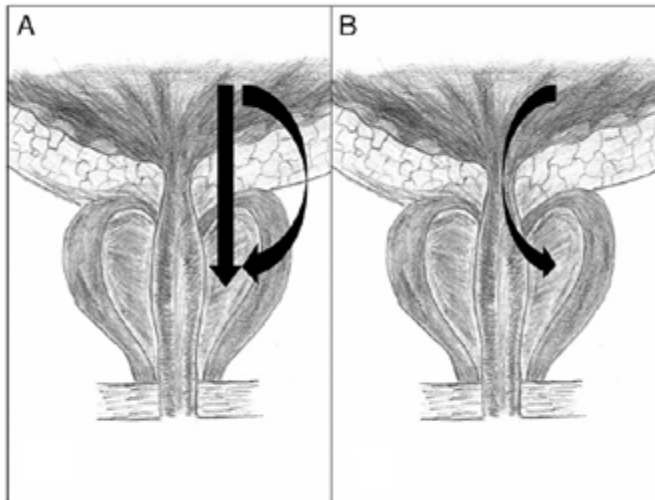


Figure 1. Prostatic invasion from urinary bladder cancer via direct transmural and extravesical route (A) and transurethral invasion (B). From: Patel AR, Cohn JA, El Latif AA, et al. Validation of new AJCC exclusion criteria for subepithelial prostatic stroma invasion from pT4a bladder urothelial carcinoma. *J Urol.* 2013;189:53-58. Reproduced with permission.

References

1. Amin MB, Edge SB, Greene FL, et al., eds. *AJCC Cancer Staging Manual*. 8th ed. New York: Springer; 2017.
2. Brierley JD, Gospodarowicz MK, Wittekind C, et al., eds. *TNM Classification of Malignant Tumours*. 8th ed. Oxford, UK: Wiley; 2016.
3. Jimenez RE, Keane TE, Hardy HT, Amin MB. pT1 urothelial carcinoma of the bladder: criteria for diagnosis, pitfalls, and clinical implications. *Adv Anat Pathol.* 2000;7(1):13-25.
4. Amin MB, Murphy WM, Reuter VE, et al. Controversies in the pathology of transitional cell carcinoma of the urinary bladder. Part II, Chapter 5. In: Rosen PP, Fechner RE, eds. *Reviews of Pathology*. Vol. 2. Chicago, IL: ASCP Press; 1997;71-110.
5. Patel AR, Cohn JA, El Latif AA, et al. Validation of new AJCC exclusion criteria for subepithelial prostatic stroma invasion from pT4a bladder urothelial carcinoma. *J Urol.* 2013;189:53-58.

E. Lymphovascular Invasion

Urothelial carcinoma may invade blood vessels or lymphatic channels. Lymphovascular invasion has been shown to be an independent predictor of recurrence and decreased overall survival.¹ In suspicious cases, blood vessels can be highlighted by immunohistochemical staining for factor VIII-related antigen, CD31 or CD34. Staining will not resolve the problem of differentiating lymphatic versus artifactual space entrapment by tumor cells, and as mentioned, this is frequently seen in urothelial tumors invading the lamina propria. Retraction artifact is also prominent in the “micropapillary variant” of urothelial carcinoma.²

References

1. Lotan Y, Gupta A, Shariat SF, et al. Lymphovascular invasion is independently associated with overall survival, cause-specific survival, and local and distant recurrence in patients with negative lymph nodes at radical cystectomy. *J Clin Oncol*. 2005;23:6533-6539.
2. Amin MB, Young RH. Intraepithelial lesions of the urinary bladder with a discussion of the histogenesis of urothelial neoplasia. *Semin Diagn Pathol*. 1997;14(2):84-97.

F. Margins

Resection margins, including those mentioned in Note A, should be carefully specified. Statements about deep soft tissue margins should specify whether peritoneal surfaces are involved by tumor. In cases of urachal adenocarcinoma in which partial cystectomy with excision of the urachal tract and umbilicus is performed, the margins of the urachal tract, ie, the soft tissue surrounding the urachus and the skin around the umbilical margin, should be specified.

G. TNM and Stage Groupings

The TNM Staging System for carcinomas of the urinary bladder of the AJCC is recommended.¹ A cystoprostatectomy specimen may contain three separate primaries: carcinoma of the urinary bladder, carcinoma of the prostate and carcinoma of the urethra. Depending on the pathology in a given case, the number of protocols to be used in a cystoprostatectomy specimen will vary.

By AJCC convention, the designation “T” refers to a primary tumor that has not been previously treated. The symbol “p” refers to the pathologic classification of the TNM, as opposed to the clinical classification, and is based on gross and microscopic examination. pT entails a resection of the primary tumor or biopsy adequate to evaluate the highest pT category, pN entails removal of nodes adequate to validate lymph node metastasis, and pM implies microscopic examination of distant lesions. Clinical classification (cTNM) is usually carried out by the referring physician before treatment during initial evaluation of the patient or when pathologic classification is not possible. Pathologic staging is usually performed after surgical resection of the primary tumor. Pathologic staging depends on pathologic documentation of the anatomic extent of disease, whether or not the primary tumor has been completely removed. If a biopsied tumor is not resected for any reason (eg, when technically unfeasible) and if the highest T and N categories or the M1 category of the tumor can be confirmed microscopically, the criteria for pathologic classification and staging have been satisfied without total removal of the primary cancer.

Primary Tumor (T) (Figure 2)

The suffix “m” should be added to the appropriate T category to indicate multiple tumors. The suffix “is” may be added to any T to indicate the presence of associated carcinoma in situ.

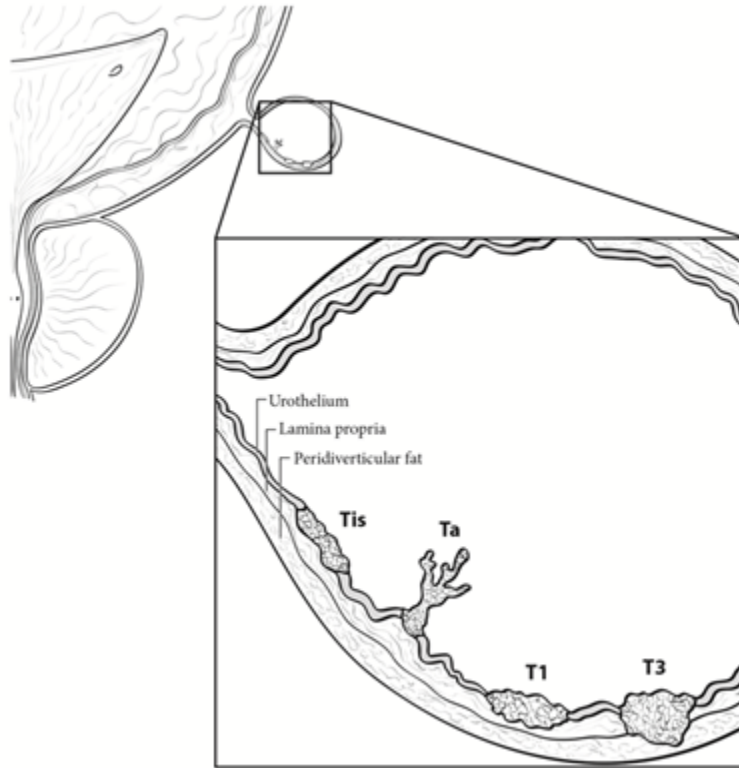


Figure 2. Extent of Tis, Ta, T1, and T3. From: Amin MB, Edge SB, Greene FL, et al, eds. *AJCC Cancer Staging Manual*. 8th ed. New York, NY: Springer; 2017. Reproduced with permission.

TNM Descriptors

For identification of special cases of TNM or pTNM classifications, the “m” suffix and “y” and “r” prefixes are used. Although they do not affect the stage grouping, they indicate cases needing separate analysis.

The “m” suffix indicates the presence of multiple primary tumors in a single site and is recorded in parentheses: pT(m)NM.

The “y” prefix indicates those cases in which classification is performed during or following initial multimodality therapy (ie, neoadjuvant chemotherapy, radiation therapy, or both chemotherapy and radiation therapy). The cTNM or pTNM category is identified by a “y” prefix. The ycTNM or ypTNM categorizes the extent of tumor actually present at the time of that examination. The “y” categorization is not an estimate of tumor prior to multimodality therapy (ie, before initiation of neoadjuvant therapy).

The “r” prefix indicates a recurrent tumor when staged after a documented disease-free interval, and is identified by the “r” prefix: rTNM.

Additional Descriptors

Residual Tumor (R)

Tumor remaining in a patient after therapy with curative intent (eg, surgical resection for cure) is categorized by a system known as R classification, shown below.

- RX Presence of residual tumor cannot be assessed
- R0 No residual tumor
- R1 Microscopic residual tumor
- R2 Macroscopic residual tumor

For the surgeon, the R classification may be useful to indicate the known or assumed status of the completeness of a surgical excision. For the pathologist, the R classification is relevant to the status of the margins of a surgical resection specimen. That is, tumor involving the resection margin on pathologic examination may be assumed to correspond to residual tumor in the patient and may be classified as macroscopic or microscopic according to the findings at the specimen margin(s).

References

1. Amin MB, Edge SB, Greene FL, et al., eds. *AJCC Cancer Staging Manual*. 8th ed. New York: Springer; 2017.